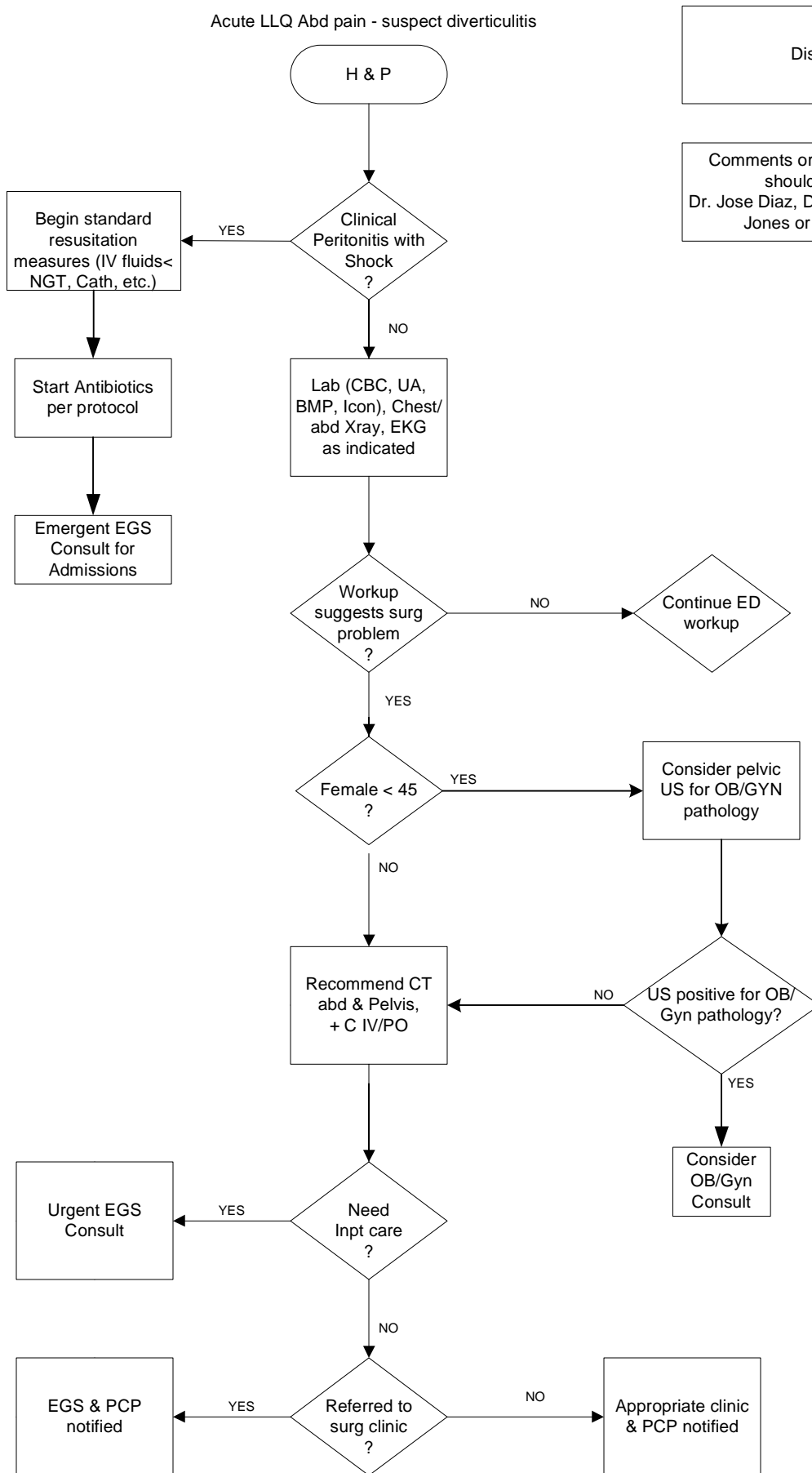


LEFT LOWER QUADRANT ABDOMINAL PAIN

Acute LLQ Abd pain - suspect diverticulitis



Disclaimer:

Comments or suggested changes should be made to:
 Dr. Jose Diaz, Dr. Willie Melvin, Dr. Ian Jones or Dr. Seth Wright